



International
Federation
of Neuroendoscopy

TRANSFORMED FROM ISGNE SINCE 2001

Changes In Arachnoid Cyst Volume Following Successful Endoscopic Fenestration In Symptomatic Children

M. Pitsika, S. Sgouros

“Mitera” Childrens Hospital, Athens, Greece



Introduction



- Symptomatic arachnoid cyst management: Endoscopic Fenestration
- Following successful endoscopic fenestration the cyst does not collapse
- Does it reach an equilibrium state?
- Aim: Assess volume change of symptomatic arachnoid cyst following endoscopic fenestration in the paediatric population



Methods and Material

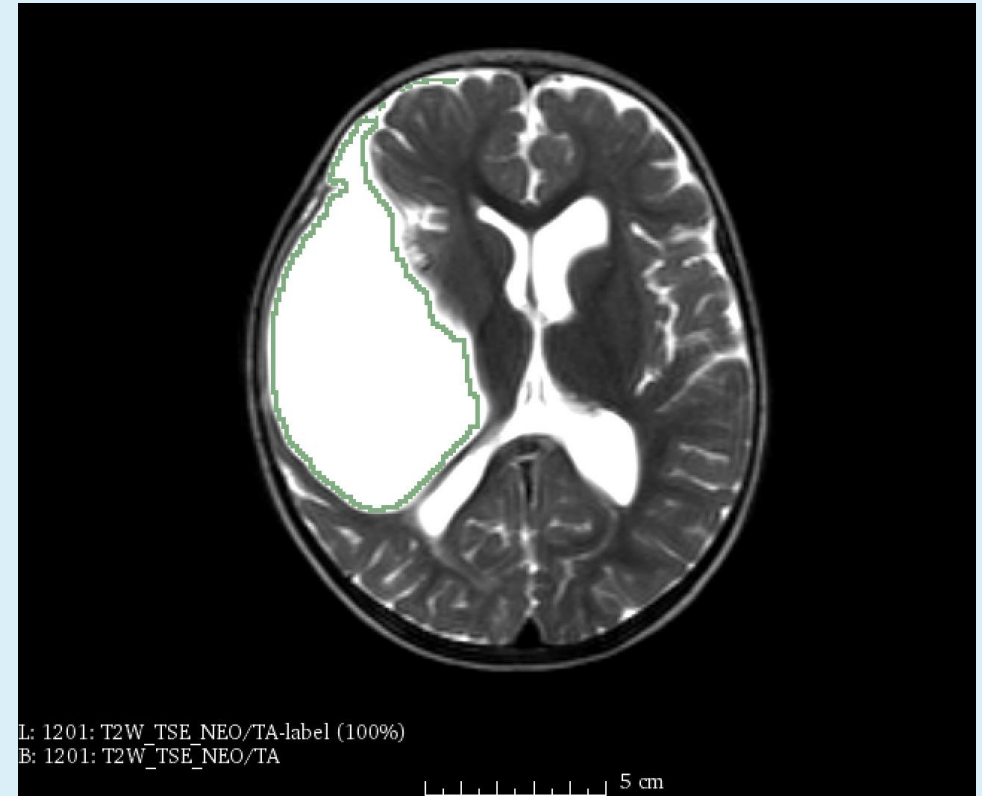
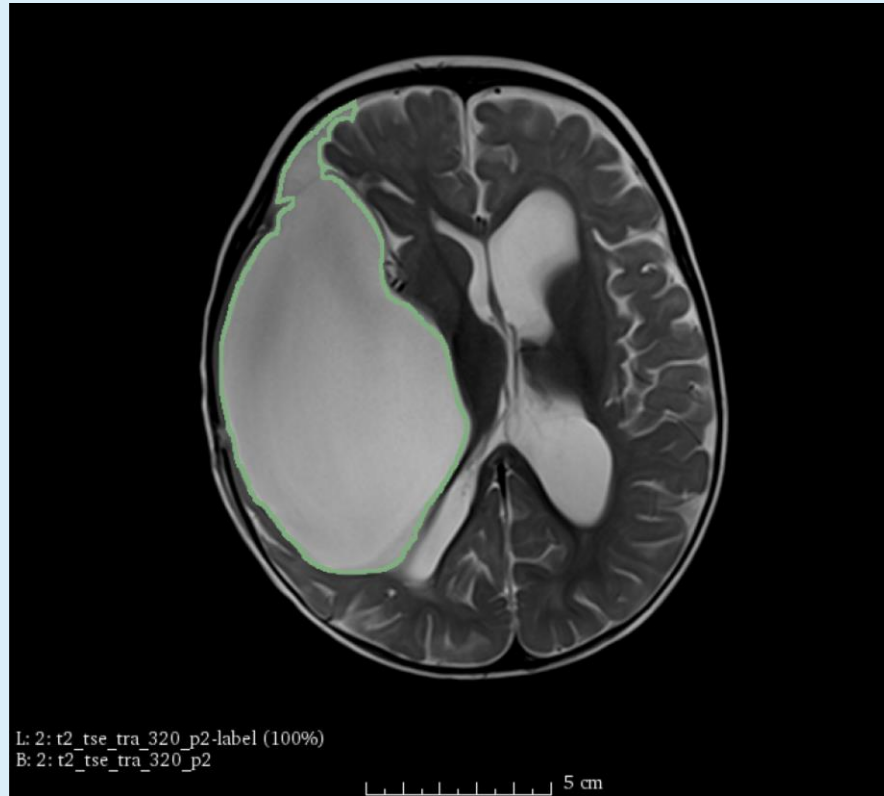
- 4 children (M:3, F:1), between 2009-2014, average age 29.25m (range 8-82)
- Location: middle fossa n=2, choroidal fissure n=1 and posterior fossa n=1
- Follow up : 25.5 months (range: 3-48)
- Symptom resolution : 100%
- Serial cyst volume measurement with semi-automatic segmentation on DICOM data
- Seed growing technique with manual correction

Patient 1

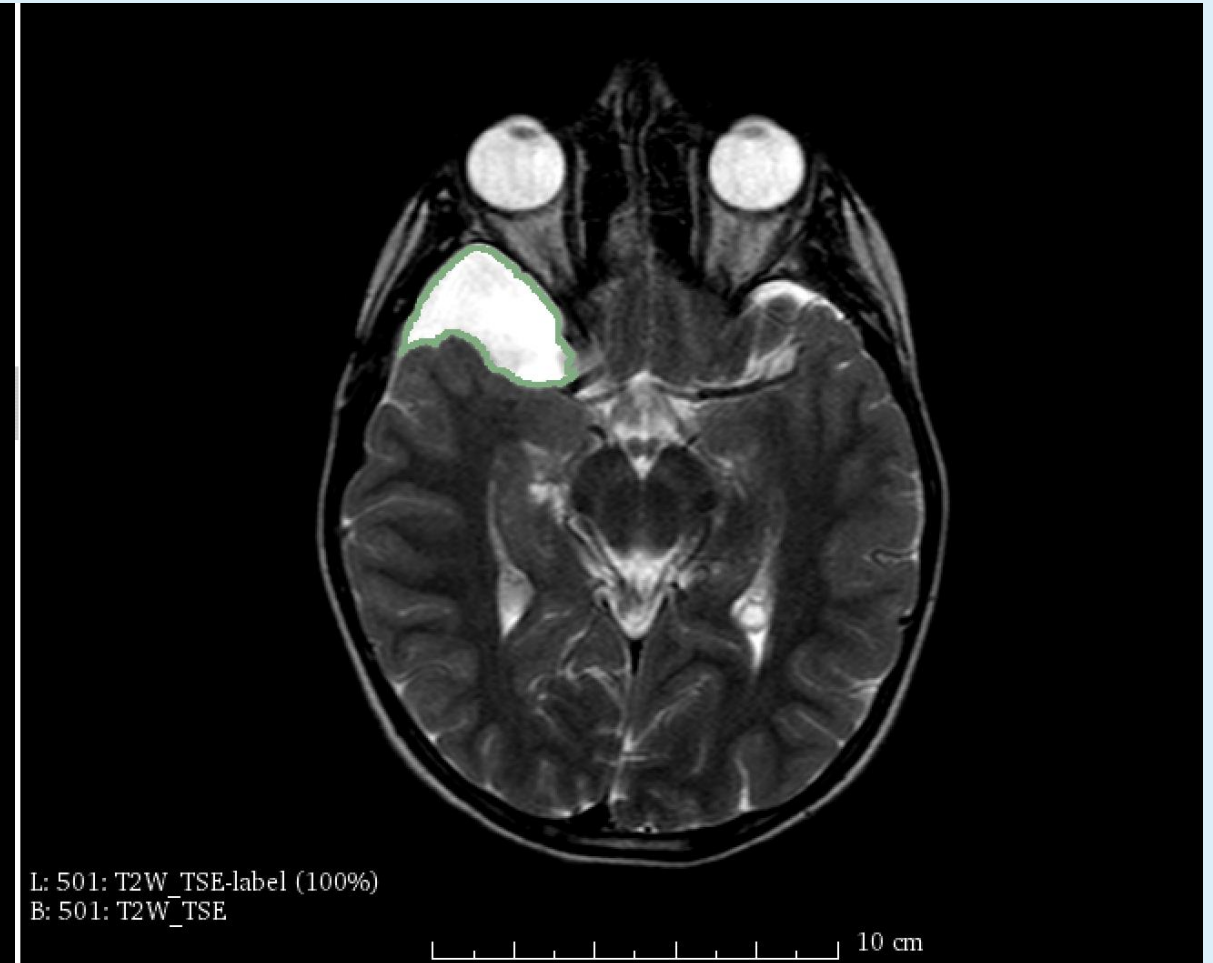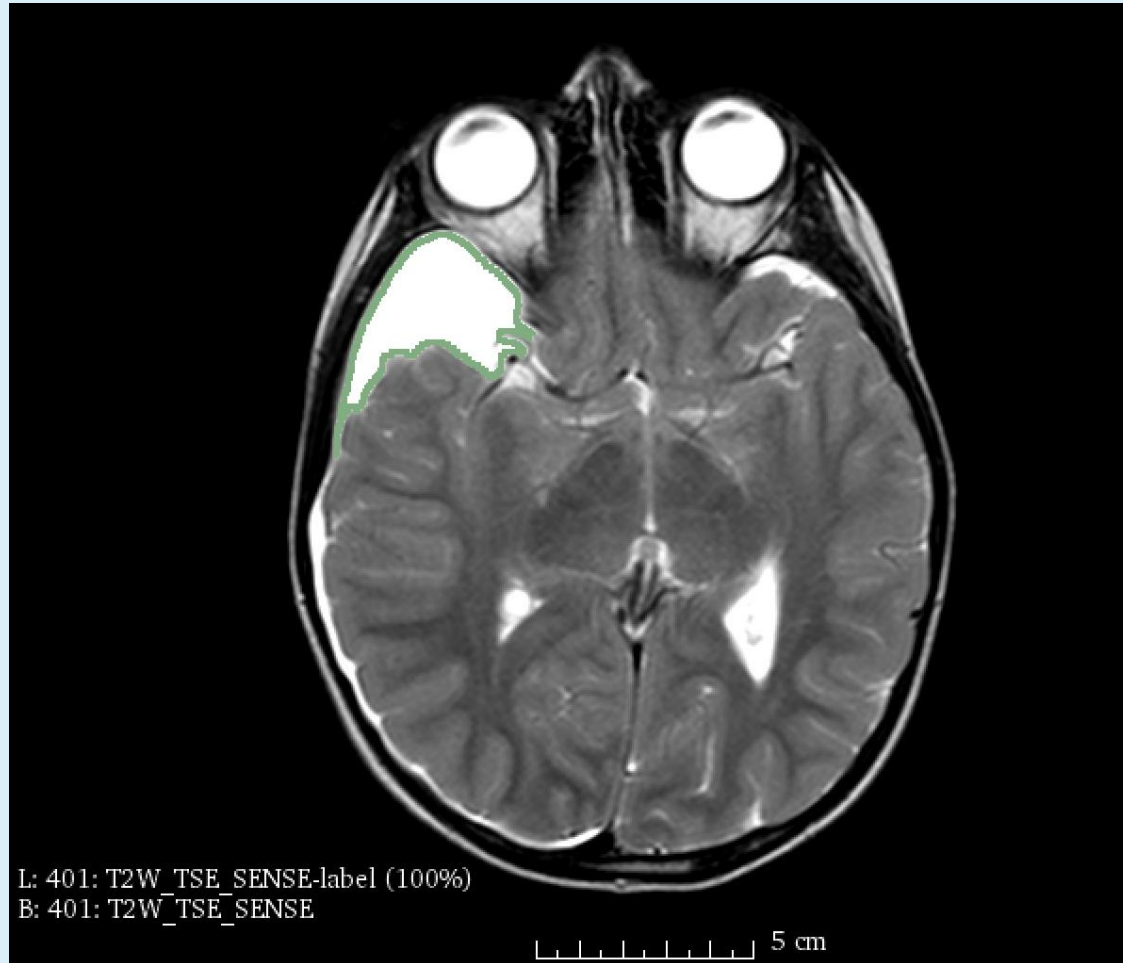


International
Federation
of Neuroendoscopy

TRANSFORMED FROM ISQNE SINCE 2001



Patient 4



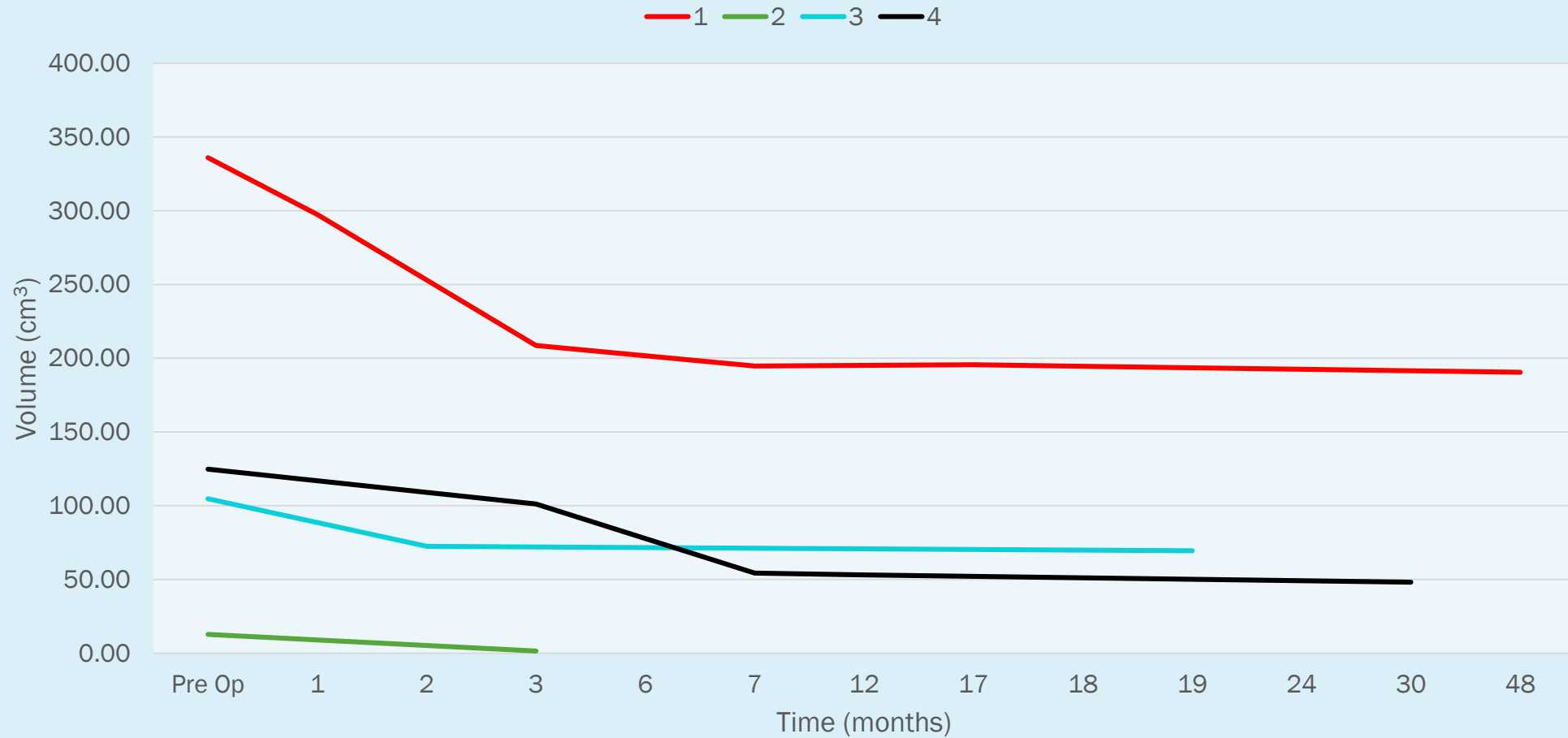
Results



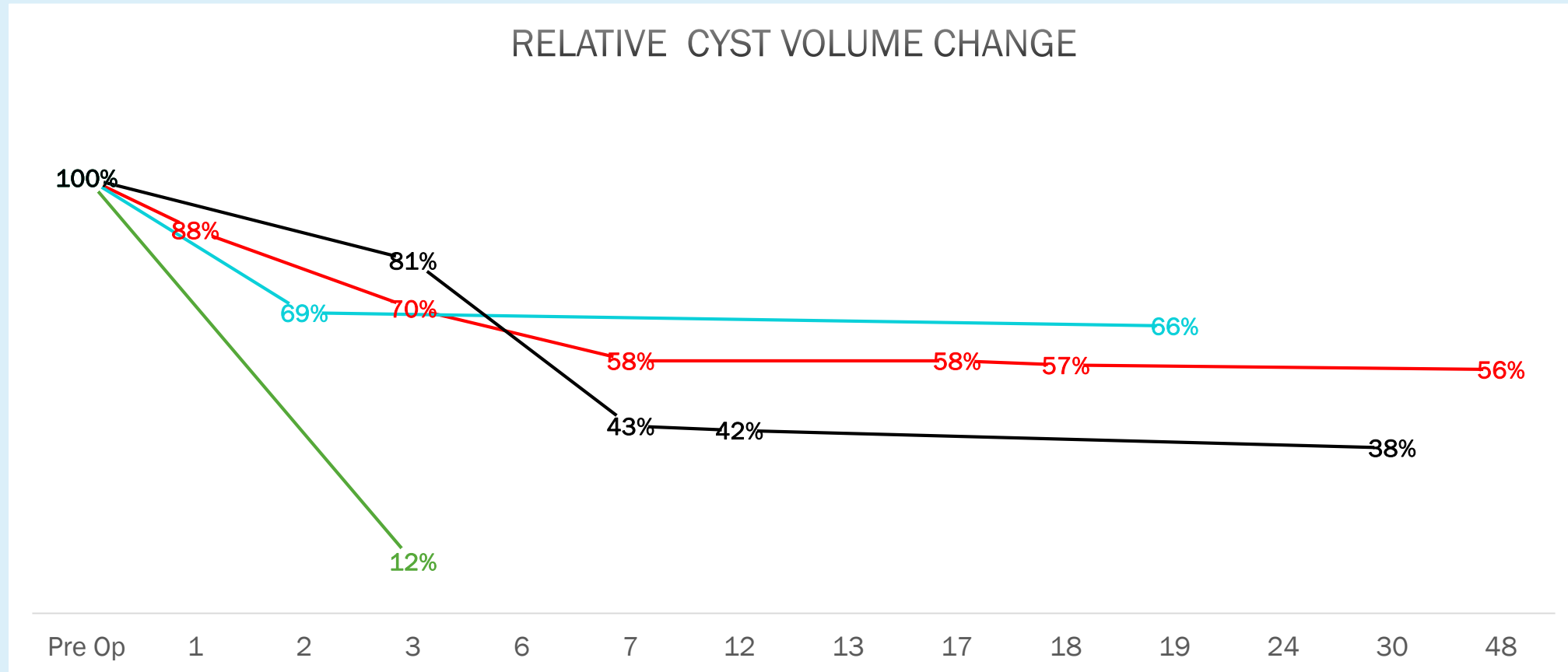
Months	Pre Op	1	2	3	6	7	12	19	30	48
Patient 1	336.01	297.35		208.701		194.618		194.56		190.46
Patient 2	12.64			1.51						
Patient 3	104.68		72.37					69.52		
Patient 4	124.81			101.21		54.33	53.02		48.1	



Results



Results



Discussion

- Cyst volume decreases gradually in the first 3 months
- Volume reaches a plateau by 7 months
- No late increase in volume
- Limitation : Small series



Conclusion



- In patient who experience symptom resolution there is significant reduction in cyst volume in the first months, reaching a plateau by 7 months
- Complete resolution of symptoms in the presence of residual volume may indicate that cyst size below a threshold may not directly correlate with clinical symptoms

