



8th World Congress
of Neuroendoscopy



International
Federation
of Neuroendoscopy

Sergey Abeshaus MD Galilee Medical Center, Israel

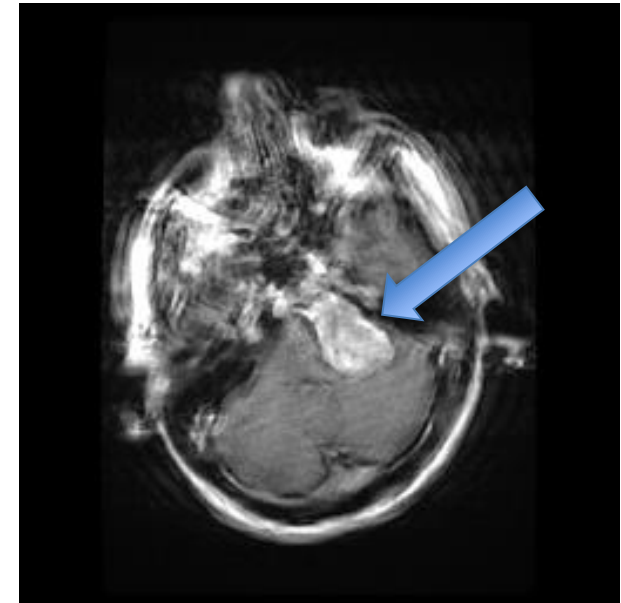
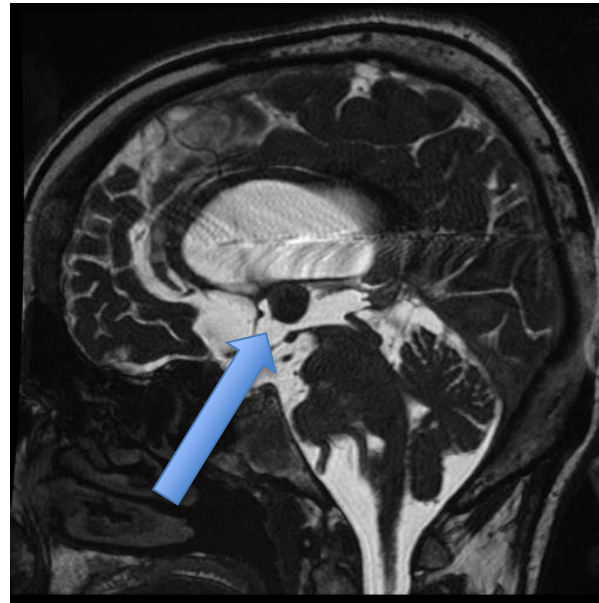
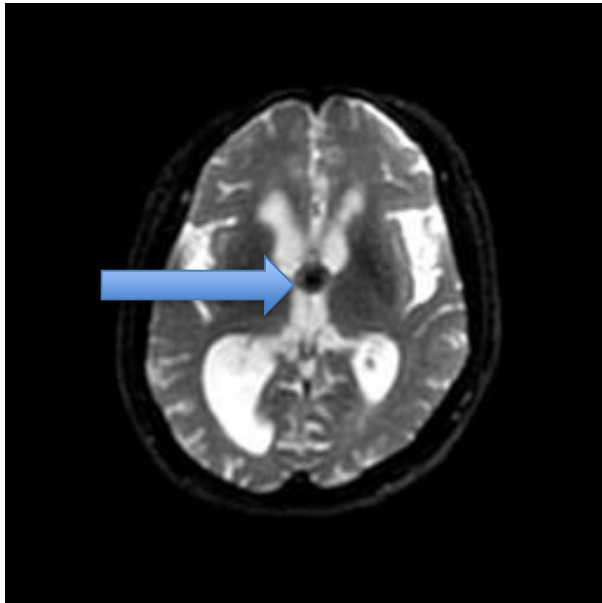
Spontaneous resolution of a iatrogenic metastasis
of colloid cyst - case report



Galilee
Medical Center

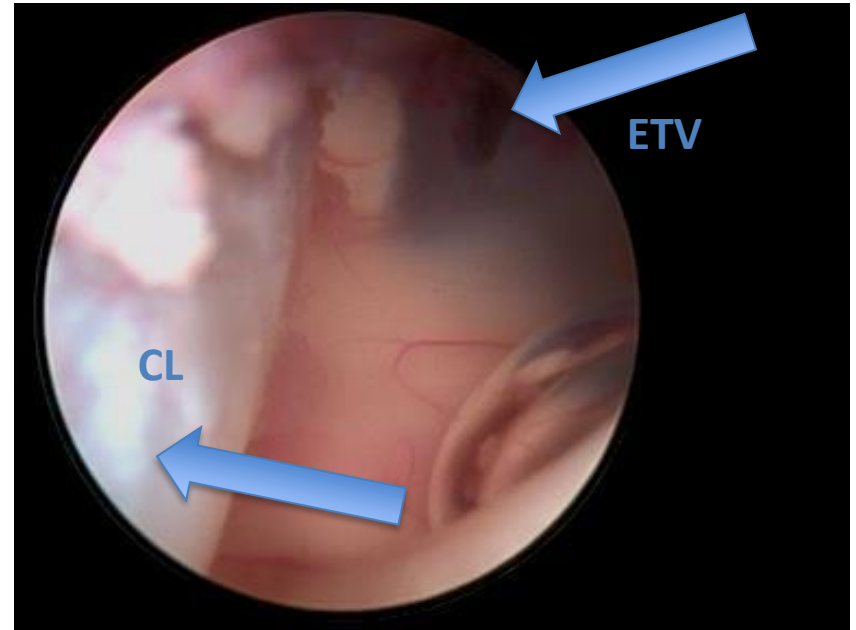
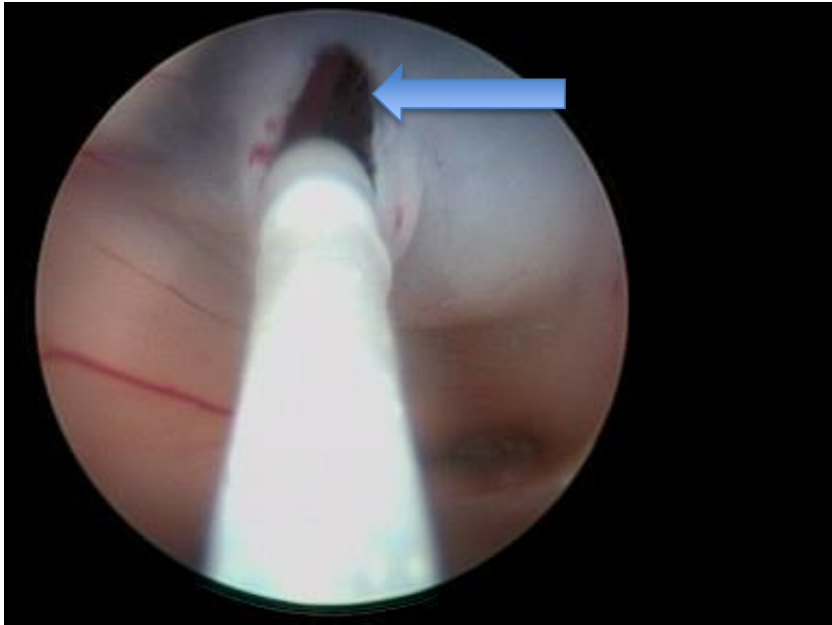
Presentation

41 y/o female suffering from headaches and left hearing loss



Surgery

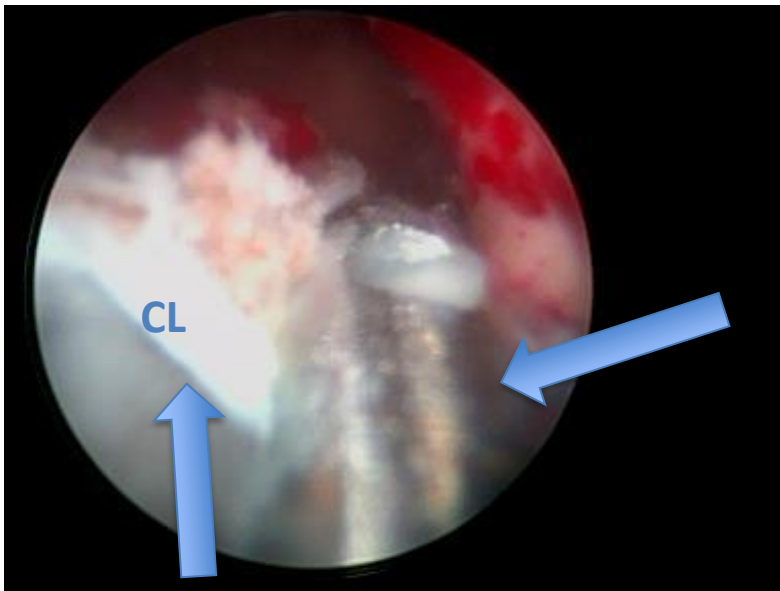
- ETV



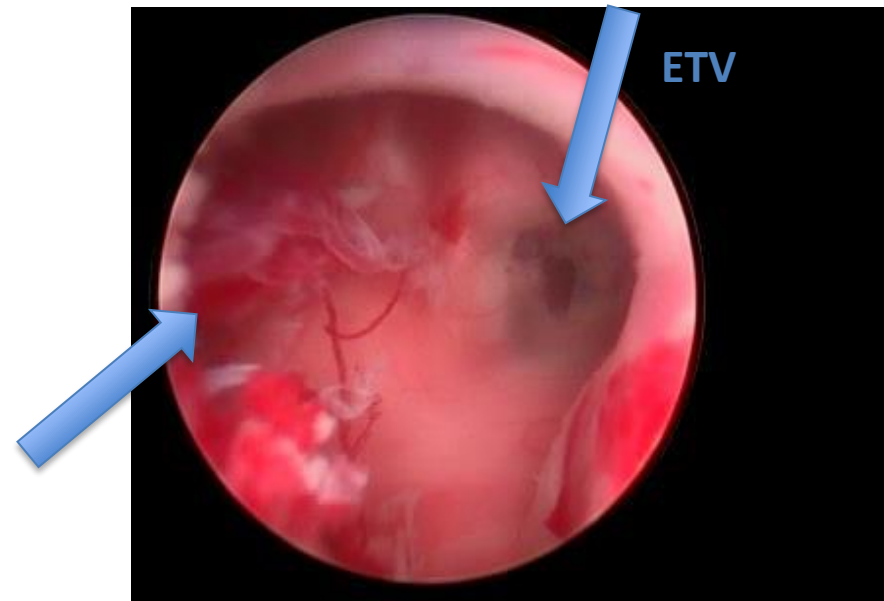
Surgery

-Colloid cyst (CL) removal

Grasping with forceps

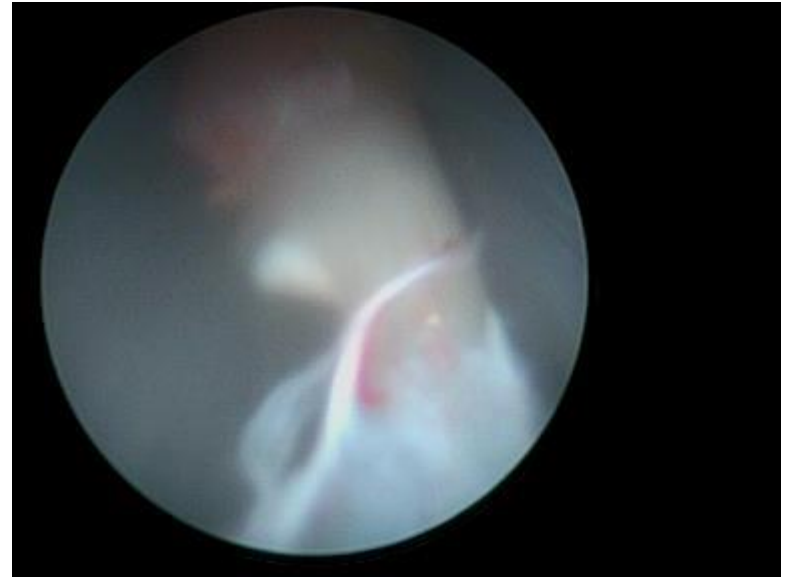
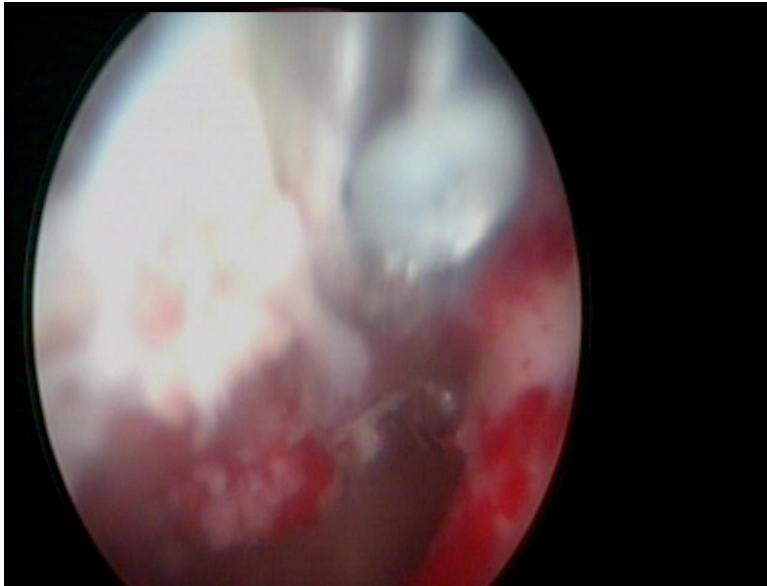


Immediate post resection view



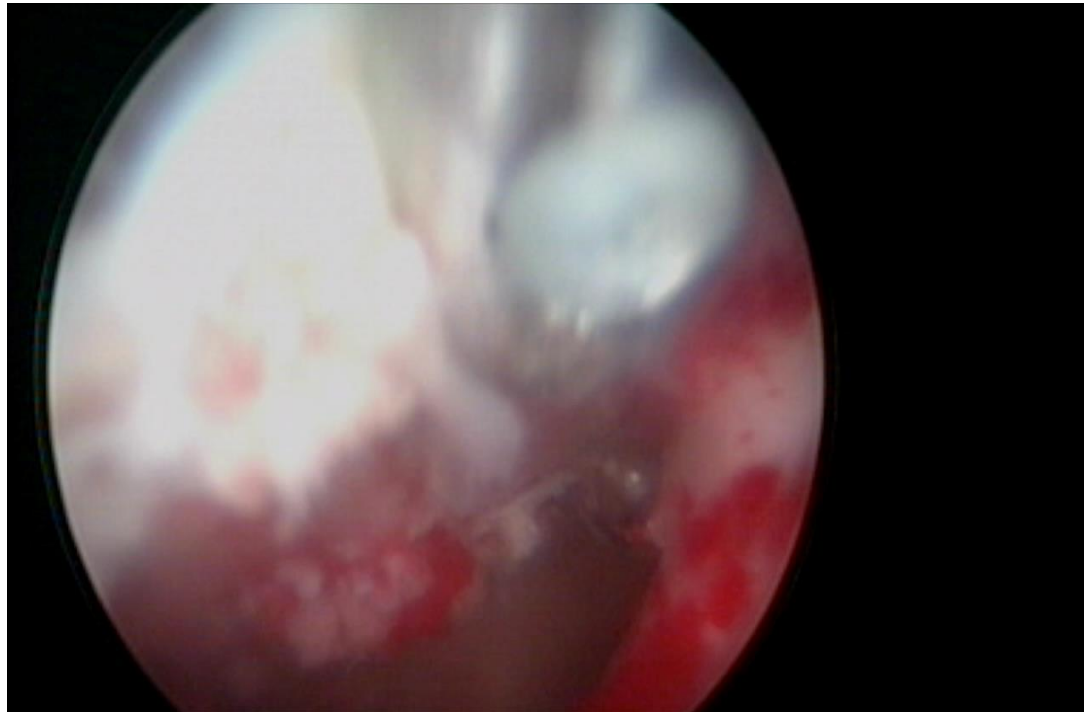
Surgery

- Loss control of the forceps with the last part of the lesion
- iatrogenic metastasis of the colloid cyst



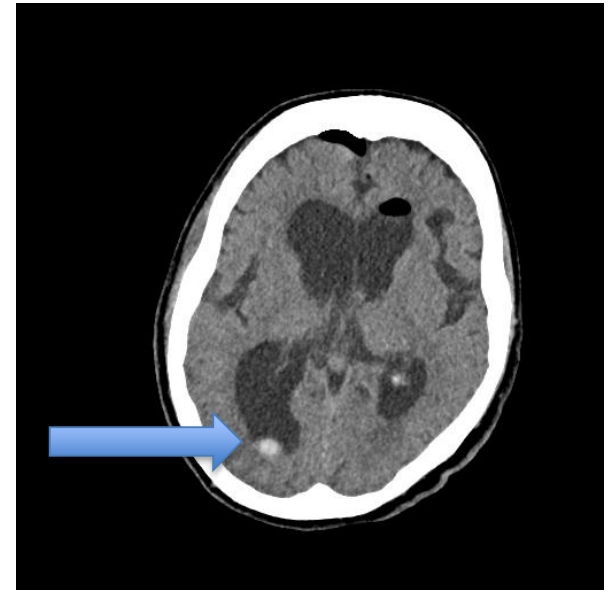
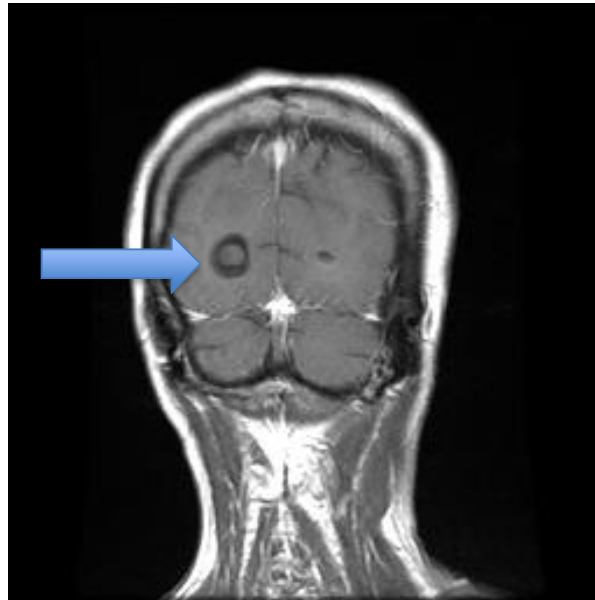
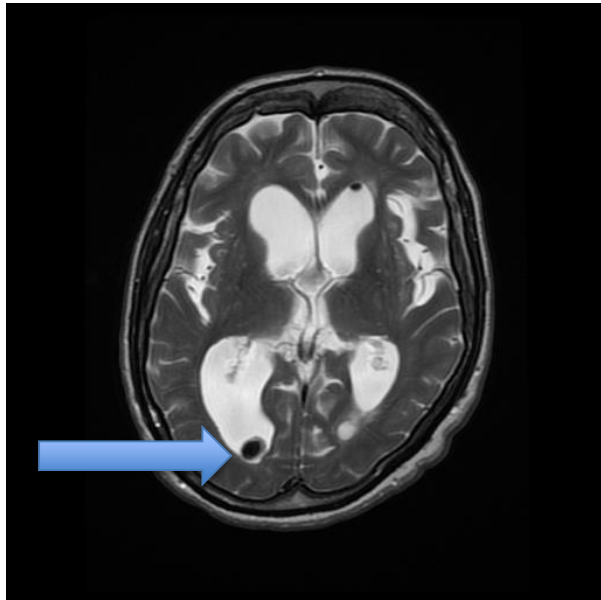
Surgery

- Loss control of the forceps with the last part of the lesion
- iatrogenic metastasis of the colloid cyst



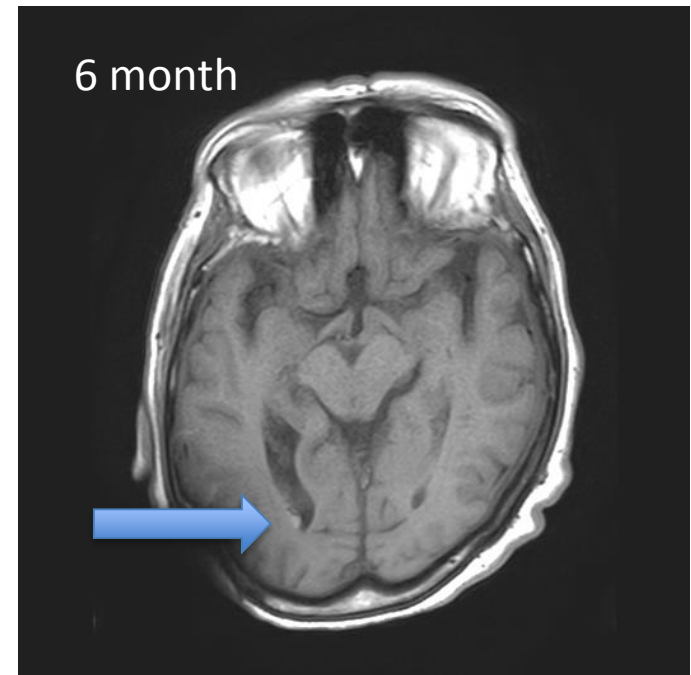
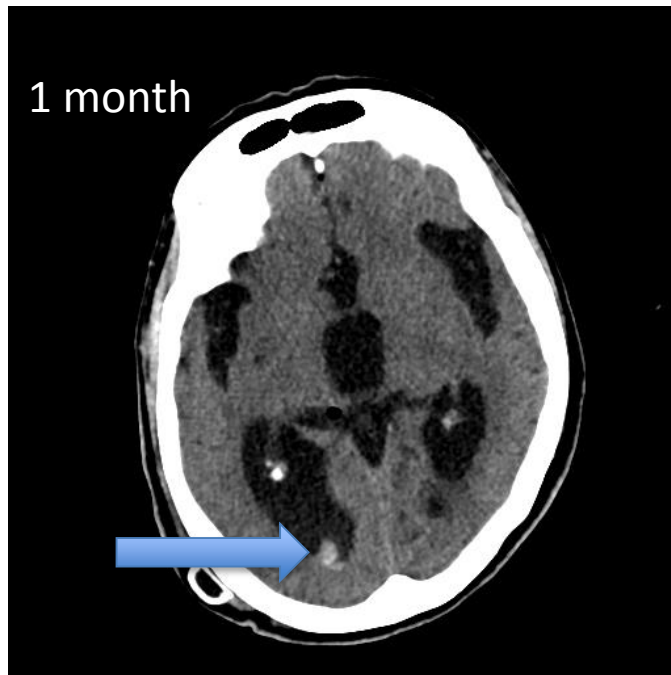
Post-OP Imaging

- Iatrogenic metastasis of the colloid cyst in the right occipital horn



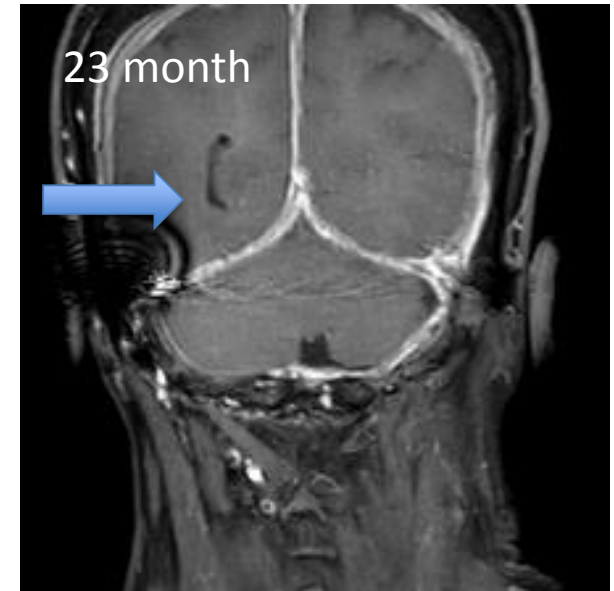
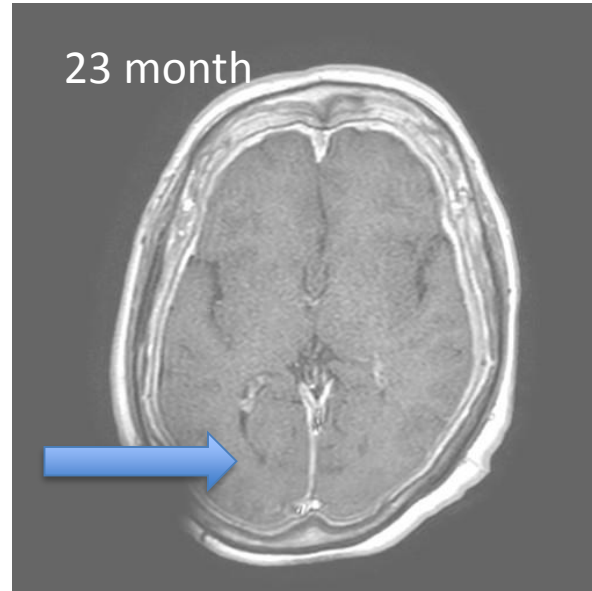
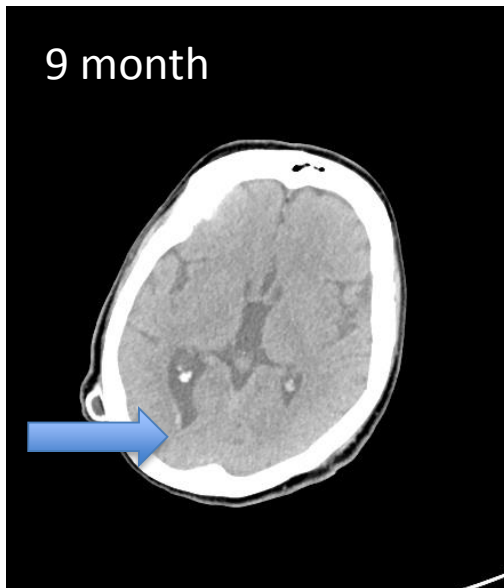Follow-Up Imaging

- Gradual resolution of the cyst metastasis



Follow-Up Imaging

-Gradual resolution of the cyst





Conclusion

According to our very limited experience,
once detached from its vascular bed,
colloid cyst will undergo spontaneous resolution

Thank you for your attention!